

Case study:

Deep Vein Arterialization for Treatment of Necrotic Left Heel Ulcer

By Kumar Madassery, MD



Kumar Madassery, MD

Rush University Medical Center
1725 W Harrison St.
Professional Building, Suite 450
Chicago, IL, 60612
(312) 563-4238

Kumar Madassery, MD, is the director of Peripheral Vascular Intervention and the CLTI Limb Salvage Program in the RUSH University System for Health. He is also an associate professor of Vascular Interventional Radiology and is the director of the Advanced Vascular Interventional Radiology Fellowship at RUSH.

History

A 40-year-old male patient came to RUSH with a large, non-healing necrotic left heel ulcer. This was secondary to his chronic limb-threatening ischemia (CLTI), which is considered terminal stage of peripheral arterial disease (PAD). The patient also had diabetes and end-stage renal failure. Although CLTI typically affects patients after the age of 60, it is not uncommon anymore to find younger patients in this disease state.

Presentation and Examination

The patient consulted with vascular specialists at two other outside hospitals prior to coming to RUSH. He was told that his only option was a below-the-knee amputation (BKA), as his diabetes and end-stage renal failure had resulted in small vessel disease pattern of the arteries in his foot.

The patient reported several weeks of severe pain in the heel and parts of the foot, which was not well managed with narcotics or other treatments.

Because of his existing comorbidities, there are no conventional or even complex arterial endovascular or surgical bypass options for his condition, also referred to as a “desert foot”. Patients such as this one typically undergo a major amputation, either BKA or even above-the-ankle (AKA), depending on the location of the tissue compromise and existing perfusion. His ulcer was mostly necrotic and covered his entire heel, extended towards the hindfoot and cranially towards the supra-calcaneal region.

Treatment

When reviewing the outside hospitals' non-invasive studies and prior angiogram images, the patient had complete occlusion of the posterior tibial artery and much of the peroneal artery, with only perfusion to the foot by the patent anterior tibial artery. Therefore, the patient had no direct or even indirect perfusion to the heel area and the location of his ulcer, which is consistent with a desert heel.

I discussed the option of performing a percutaneous deep vein arterialization (DVA) to the patient's foot with the patient, his family and referring providers. When a DVA is performed, an endovascular connection is made between a tibial artery and adjacent tibial vein, followed by other endovascular techniques to direct blood flow down towards the foot through the veins. If successful, after a few weeks, new arterial vessel formation can be seen.

The patient was brought to the interventional radiology suite, and with anesthesia assistance, the procedure was undertaken. In order to perform the DVA, arterial access was obtained in the left lower extremity, as well as a second access in the plantar vein of the foot.

Next, a suitable crossover site for the arterio-venous connection was chosen. Once the crossover was successfully made using combination of re-entry devices, balloons, snares and guidewires, the outflow vein (in this case, the posterior tibial vein), was aggressively angioplastied to disrupt the venous valves, followed by covered stent placement. This allows possibility of blood flow down the vein towards the foot, rather than up the vein as is naturally the case.

After this, careful navigation of the venous outflow channels in the ankle and foot had to be navigated, to find the best outflow vein to return the blood back up the leg. After coil embolization of a competing collateral vein, the procedure was completed. A completion angiogram showed intact blood flow from the proximal tibial artery down the posterior tibial vein and towards the midfoot.

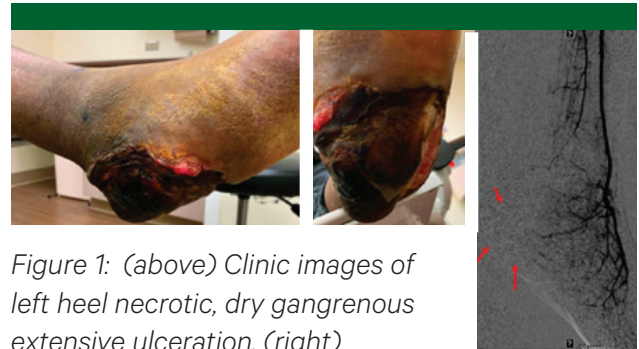

Figure 1: (above) Clinic images of left heel necrotic, dry gangrenous extensive ulceration. (right) Angiogram of left foot before DNA showing lack of adequate perfusion to the heel region (red arrow)

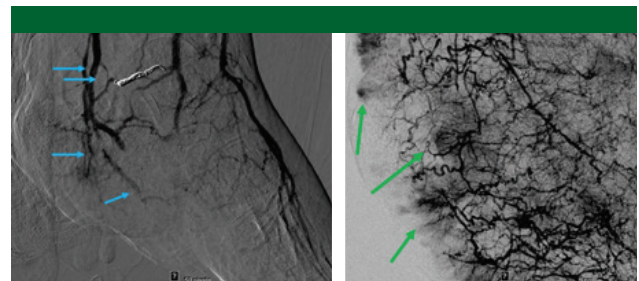


Figure 2: (left) Immediate completion post-DVA angiogram showing new venous perfusion towards the foot (blue arrow). (Right) Interval angiogram at approximately 4-5 months showing robust arteriogenesis and multiple areas of wound blush (green arrows) in the wound bed. This is despite the DVA being occluded.

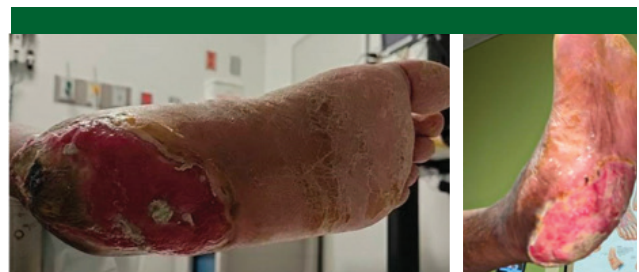

Figure 3: Interval images showing marked improvement with granulating tissue present throughout majority of the wound.

Outcome

The patient was monitored in an interventional observation unit overnight and discharged the next day, with close virtual and telephone follow-ups with the patient and his providers. Within two weeks, the patient reported his pain was gone.

Over the course of the next three months, he had intermittent debridements by his podiatrist. In addition, he had a surveillance ultrasound around 15 weeks demonstrating that the DVA was occluded; however, he was doing well. He was brought in for a diagnostic angiogram, which showed remarkable new arterial blood vessel formation in the hindfoot/heel despite the DVA being occluded, thus the DVA had done its job.

Long-term Outcome

After approximately 20 weeks, the patient is almost completely healed with no further tissue loss and he remains pain free. He will have a skin substitute graft applied for a small remaining region of the wound as he has robust granulation tissue and no signs of infection.

What is deep vein arterialization?

DVA involves the percutaneous creation of a connection between the tibial artery and the vein, followed by several additional steps to direct blood flow into the foot. This procedure, which is relatively novel, has gained interest and adoption globally, but is mostly performed at highly experienced complex CLI/CLTI centers, such as RUSH, where my team and I have performed the majority of DVAs in Chicago.

Since its adoption, many properly selected patients have successfully had limb salvage or limb preservation with DVA when otherwise facing major amputation. Further iterations of this procedure such as a distal DVA have been undertaken by many of us to reduce some of the expected sequelae, such as pedal edema, and the need for covered stents seen with conventional proximal DVA.

How does it work?

The exact cellular mechanism is yet to be understood. It is proposed that the new increased flow of highly oxygenated arterialized blood flow to the capillaries of tissues that were chronically ischemic induces angiogenesis in that distribution. There are current ongoing trials with a proprietary system for DVA creation currently in process; however, most often this is being done with off-the-shelf equipment. Regardless of approach, after creation, it is estimated that at least four-to-six weeks is needed to create a majority of the new angiogenesis for success.

When is it used?

This approach is for patients who are deemed to have no true options for arterial revascularization, which should be determined by experienced vascular specialists. It is not uncommon that patients are often deemed as having “no option,” which can be due to providers’ lack of experience and success with complex CLTI cases, insufficient equipment and, in some cases, an unwillingness to refer to advanced practitioners. Many patients such as this sent to our team have been successfully revascularized without the need for DVA.

If it is determined that the patient is deemed to truly have no advanced arterial options, does not have grossly or systemically infected wounds and our collaborative team feels overall that the wound has at least a few weeks of stability, then DVA may be offered.

Analysis

Percutaneous DVA has the possibility of reducing major amputations in patients with CLTI. This advanced and novel technique, which is constantly undergoing dynamic iterations, has become an outpatient option for patients that are facing loss of a limb.

The PROMISE II trial using the propriety LimFlo DVA creation system is the largest trial to date, with 105 patients who have now been followed to six months with 76% limb salvage and 87% overall survival. This is promising as patients with CLI/CLTI who cannot be revascularized carry an approximately 60% mortality rate at five years, which is higher than many cancers. In addition, our team will be principal investigators for the upcoming PROMISE III global trial for the proprietary system.

In the analysis of my team’s patients, I have seen an approximate 70% limb salvage rate with DVA creation, which is in line with national and global among high-level interventionalists.. These are patients who would have otherwise had a 100% chance of major amputation.

Thus, it is imperative for referring providers and patients to ask the right questions as to why something cannot be done, seek a second opinion, and see if options such as DVA have been evaluated by experienced interventionists. In doing this, we are all fighting to give our patients a chance to keep their limbs, as long as the patient and family are willing to undergo the journey.