

Gastrointestinal and Liver Pathology at Rush

1750 W. Harrison St., Suite 570, Chicago, IL 60612 ♦ (312) 942-5227 phone ♦ (312) 942-4228 fax

Case of the Month Question – February 2010

Contributed by Drs. Allison Howard and Shriram Jakate

A 65 year old Caucasian male with a past history of chronic back pain presents with nausea and abdominal pain. Upper endoscopy shows numerous discrete ulcers in the stomach (Figure 1). A biopsy from the distal stomach shows superficial ulceration and somewhat dense inflammation (Figure 2).

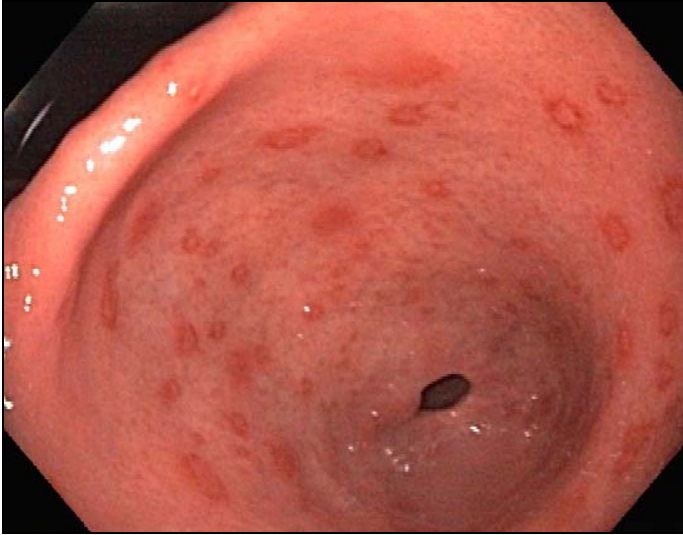


Figure 1: Endoscopy of the stomach

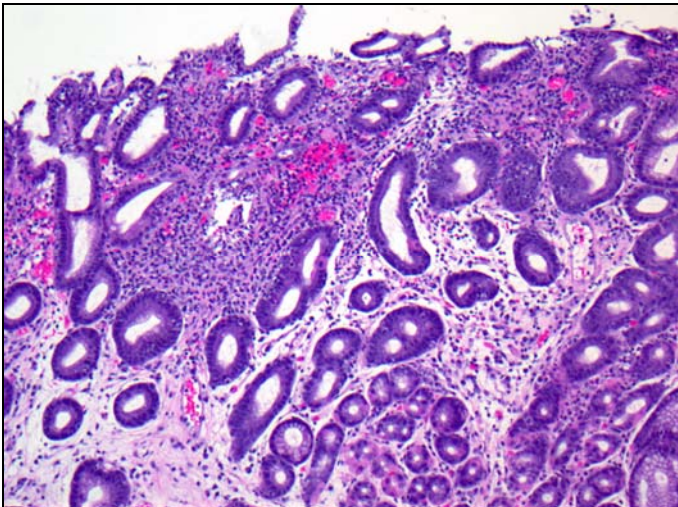


Figure 2: Microphotograph from the distal stomach (100x)