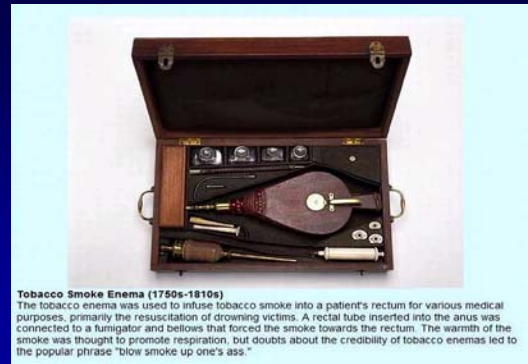

# Esophageal Cancer Surgical Options

Michael J. Liptay, MD, FACS

Associate Professor of Surgery  
Chief, Division of Thoracic Surgery  
Rush University Medical Center  
Chicago Illinois



**Tobacco Smoke Enema (1750s-1810s)**  
The tobacco enema was used to infuse tobacco smoke into a patient's rectum for various medical purposes, primarily the resuscitation of drowning victims. A rectal tube inserted into the anus was connected to a fumigator and bellows that forced the smoke towards the rectum. The warmth of the smoke was thought to promote respiration, but doubts about the credibility of tobacco enemas led to the popular phrase "blow smoke up one's ass."



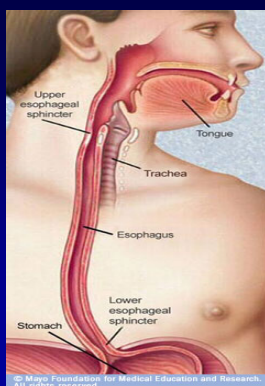
## Esophageal Cancer

- 14,500 new cases – 2006
- 10% - 5 year survival
- Lymph nodes involved – 22 months
- AdenoCA rising in incidence




## Esophageal Cancer

- Background
- Staging / Workup
- Treatment Options



### ESOPHAGUS

- Variable lymph node drainage
- Anatomy congested (aorta, heart, trachea)
- Advanced presentation of cancer




## Epidemiology of esophageal cancer

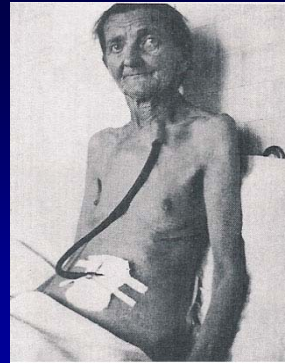
- Squamous Cell Cancer = most common worldwide
  - High incidence in China, temperate South America, Iran
- Adenocarcinoma greatest increase of any cancer past 20 years in North America
  - >60% esophageal ca in U.S.
  - Lower 1/3 of esophagus



## Franz Torek (1861-1938)



RUSH UNIVERSITY  
MEDICAL CENTER



The first patient to have transthoracic esophagectomy. Notice patient has a rubber tube as esophagus.

RUSH UN  
MEDICAL

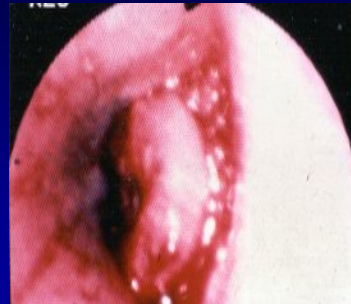## Esophagectomy: History

Torek F. The first successful case of resection of the thoracic portion of the esophagus for carcinoma.

- Long posterolateral incision (ribs 4-7)
- 2hrs 27minutes
- External Hose
- Hot Coffee, Whiskey , Strychnine

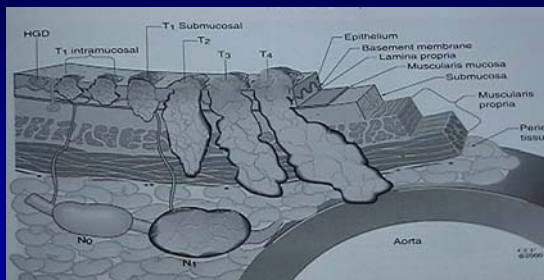
RUSH UNIVERSITY MEDICAL CENTER *Surg Gynecol Obstet 1913;16:614-7*

## Endoscopy: Esophageal CA



RUSH UNIVERSITY MEDICAL CENTER

## Esophageal Cancer Staging



RUSH UNIVERSITY MEDICAL CENTER

## Esophageal Cancer Staging

- TNM classification

Stage	I	N	M
• 0	Tis	0	0
• 1	T1	0	0
• 2A	T2	0	0
• 2B	T3	0	0
• 3	T1	1	0
• 3	T2	1	0
• 3	T3	1	0
• 4	T4	any	0
• 4	any	any	1

RUSH UNIVERSITY MEDICAL CENTER

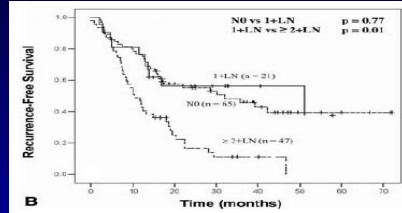
**Table 5. RELATIONSHIP BETWEEN TUMOR DEPTH AND NODE LOCATION**

Depth	Prevalence of Distant Node Disease*	Prevalence of Celiac Node Involvement†
Intramucosal	0/16 (0%)	0/16 (0%)
Submucosal	1/16 (6.25%)	0/16 (0%)
Muscularis propria	4/13 (30.8%)	3/13 (23.08%)
Transmural	22/55 (40%)	15/55 (27.27%)

\* Chi-square = 14.22, P = .0026.  
 † Chi-square = 10.46, P = .015.



## # Lymph Nodes Prognostic



**FIGURE 2.** These graphs illustrate (A) overall survival and (B) recurrence-free survival in patients who had residual adenocarcinoma of the esophagus or lymph nodes after they received preoperative chemoradiation. The overall survival and recurrence-free survival rates among patients who had 1 lymph node (LN) that was positive for metastasis (1 + LN) were similar to the rates noted among patients who had no lymph node metastasis (N0) but were significantly better than the rates among patients who had  $\geq 2$  positive LN metastases ( $\geq 2 + LN$ ).

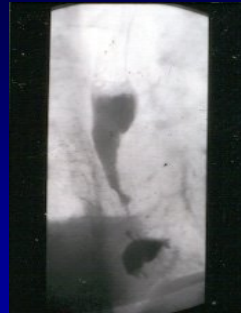

## Workup: Esophageal Cancer

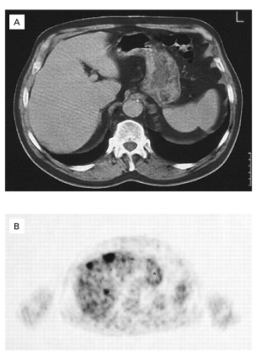
- Upper GI
- Computed Tomography
- Positron Emission Tomography (PET)
- Endoscopy
- Endoscopic ultrasound (EUS)



## UGI : Esophageal Cancer

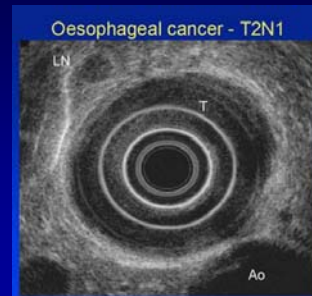


## PET Detection of Distant Mets



The preoperative CT scan revealed no metastases in the liver (Panel A), whereas the PET scan showed three hot spots in the liver (Panel B). Liver metastases were confirmed during follow-up.

## Endoesophageal Ultrasound (EUS)



## CT PET PETCT

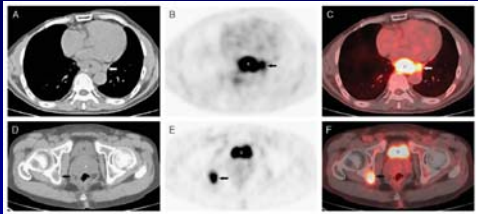


FIGURE 4. Axial CT (A), PET (B), and integrated CT-PET (C) in a 54-year-old man show increased uptake of FDG in mid-esophageal cancer (E), and local increased FDG uptake in adjacent nodes owing to metastasis (N1) (arrow). Axial CT (D), PET (E), and integrated CT-PET (F) show increased uptake of FDG in osseous metastasis (M1) (arrow). Integrated CT-PET improves accuracy of staging because of ability to detect distant metastasis. B indicates bladder.



## PET and EUS

- PET – unsuitable for detecting locoregional LNs
- PET – improves detection of Stage IV
- EUS – gold standard for T staging
- EUS – best for local LN assessment
- PET/CT – restaging after neoadjuvant



## Esophageal cancer-treatment

- Chemo-Radiation
- Chemo +/- RT → Surgery
  - Multiple trials with conflicting results
  - Ideally, performed in setting of clinical trial
- Surgical resection
  - Mainstay of therapy for esophageal cancer
  - Excellent palliation
  - Best 5 year survival of any modality
  - Which operation?



## Definitive ChemoRT trials

TABLE 1. *Definitive chemo-radiotherapy trials*

Study	Chemoradiation vs. Radiation: Survival	Duration of follow-up
RTOG 85-01 <sup>28</sup>	27% vs. 0%	>5 years
ECOG 1282 <sup>50</sup>	9% vs. 7%	5 years
NCI Brazil <sup>51</sup>	16% vs. 6%	5 years
EORTC <sup>52</sup>	12% vs. 6%	3 years

RTOG, radiation therapy and oncology group; ECOG, eastern cooperative oncology group; NCI, national cancer institute; EORTC, european organization for research and treatment of cancer.

*Ann Surg Oncol, Vol. 11, No. 7, 2004*



## Esophageal Cancer Surgery

- Multiple approaches = no clear best
  - Transthoracic
  - Transhiatal – no thoracotomy
  - Laparoscopy/Thoracoscopy
- Gastric Conduit  
Neck vs Intrathoracic anastomosis  
\*\* extent of lymph node removal



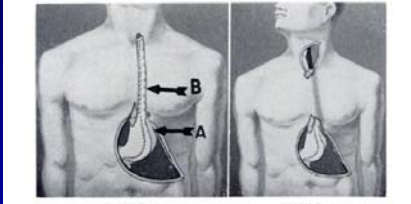
## Esophagectomy Complications

- ~3-5% mortality
- 30-40% morbidity
- Pulmonary
- Anastomotic – leak, strictures
- Gastric necrosis



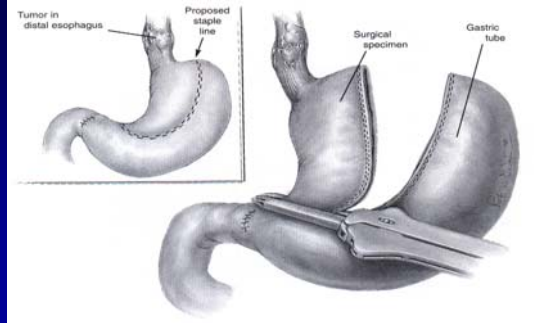
### Esophageal Replacement with a Reversed Gastric Tube

HENRY J. HEIMLICH, M.D., F.C.C.P.\*  
New Rochelle, New York



*Chest: 1959*

### Construction of Gastric conduit



### Esophagectomy Principles

- Jejunostomy tube
- Pyloric drainage
- Lymph node dissection
- Stomach preferred conduit

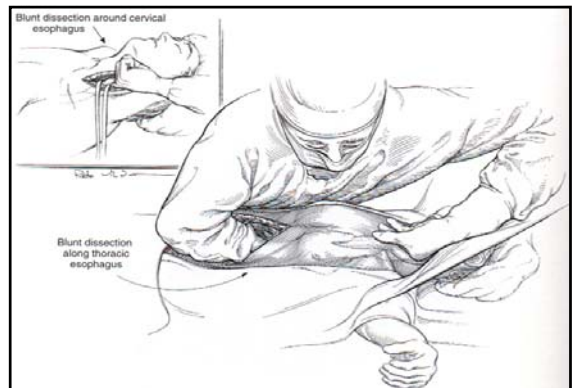
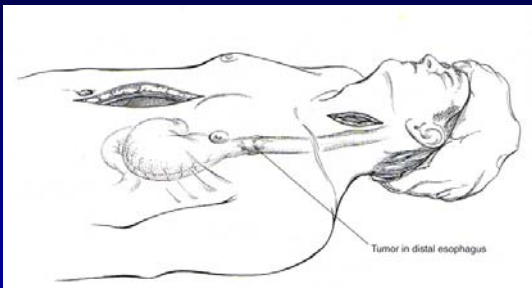


### Transhiatal Esophagectomy

- Orringer –largest series
- Less morbidity with no thoracotomy – unproven
- Relatively contraindicated for mid-esophageal lesions
- No systematic intrathoracic node dissection



### Transhiatal Esophagectomy

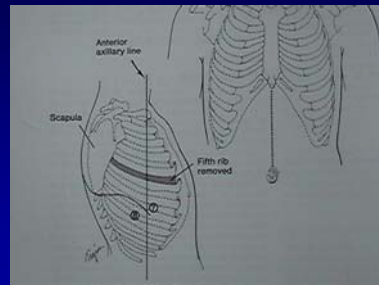


## Esophagectomy-transthoracic

- Advantages of transthoracic
  - Better visualization; ?"safer operation"
  - **More complete lymph node dissection**
- Drawbacks
  - Thoracotomy
  - Intrathoracic anastomosis



## Esophagectomy- Thoracotomy



## Thoracoscopic Esophagectomy

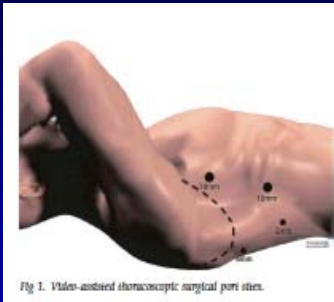


Fig 1. Video-assisted thoracoscopic surgical port sites.



## Thoracoscopic Esophagectomy

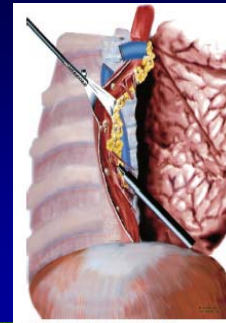


Fig 2. Thoracoscopic mobilization of the esophagus.



## Final Thoughts

- Staging : EUS and PET
- Consider neoadjuvant chemo-RT (clinical trial!) for < 70yrs
- Over 70yrs – Surgery alone
- Minimally invasive approach can speed recovery

