

Gastrointestinal and Liver Pathology at Rush

1750 W. Harrison St., Suite 570, Chicago, IL 60612 ♦ (312) 942-5227 phone ♦ (312) 942-4228 fax

Case of the Month Answer – October 2009

Contributed by Drs. Dawn Bradley and Shriram Jakate

Diagnosis: Adenosquamous carcinoma of the esophagus

Adenosquamous carcinoma (ASC) of the esophagus is a rare subtype of esophageal cancer, comprising < 1% of all esophageal cancers in the United States. Primary ASCs have been reported to develop in several other organs including lung, stomach, pancreas, and gallbladder ¹. The clinical course varies depending on the affected site ¹.

Macroscopic appearance of an ASC of the esophagus typically consists of a heterogeneous pink-red mass with ulcerations, depressions, and raised or exophytic areas (Fig. 1) ². These tumors may be associated with hemorrhage and are usually located at the GE junction.

Histological examination of ASC illustrates coexisting elements of infiltrating squamous cell carcinoma (SCC) (Fig. 2) and adenocarcinoma (AC) (Fig. 3) ¹. The World Health Organization (WHO) classifies ASC as having a significant squamous carcinomatous component that is intermingled with tubular adenocarcinoma ³. It does not specifically state a minimum ratio of these two elements. ASCs may arise in esophageal submucosal glands or ducts, and in some cases, one can identify ductal epithelial origin ⁴. These tumors are highly malignant, especially when poorly differentiated, and they can spread in a pagetoid fashion ⁴.

The differential diagnosis for ASC includes mucoepidermoid carcinoma. ASCs behave more aggressively than mucoepidermoid carcinomas. Thus, distinguishing between these two entities is paramount ⁴.

Since ASC of the esophagus is a relatively uncommon tumor, the prognosis of ASC has not been fully elucidated. However, there are few case reports of esophageal ASCs that have indicated that these tumors have a highly aggressive biological behavior with a high propensity for regional lymph node metastasis ¹. The clinical course after surgical resection has also been reported to be very short ¹.

Gastrointestinal and Liver Pathology at Rush

1750 W. Harrison St., Suite 570, Chicago, IL 60612 ♦ (312) 942-5227 phone ♦ (312) 942-4228 fax

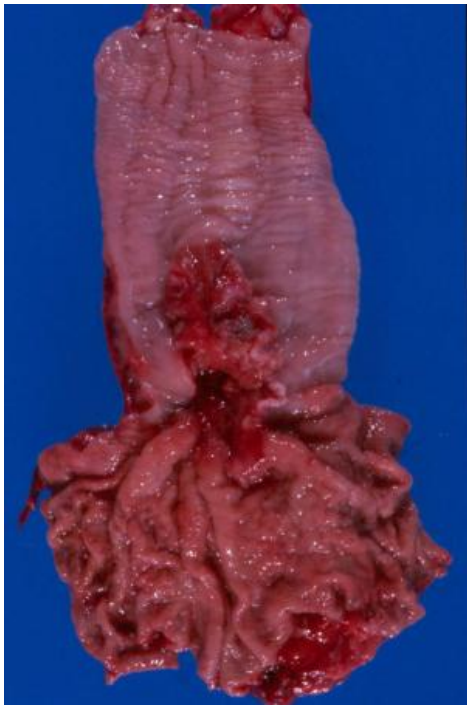

Fig. 1

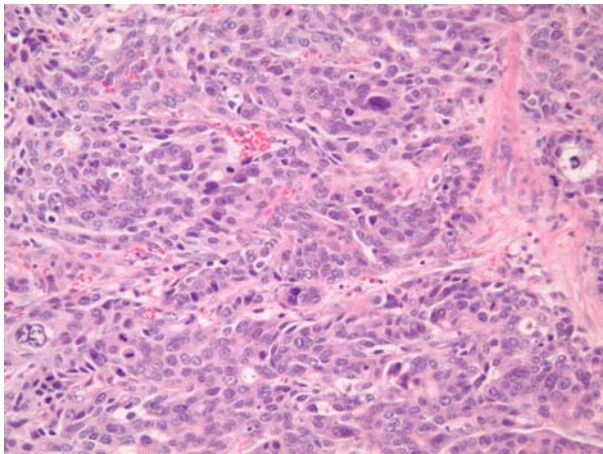


Fig. 2

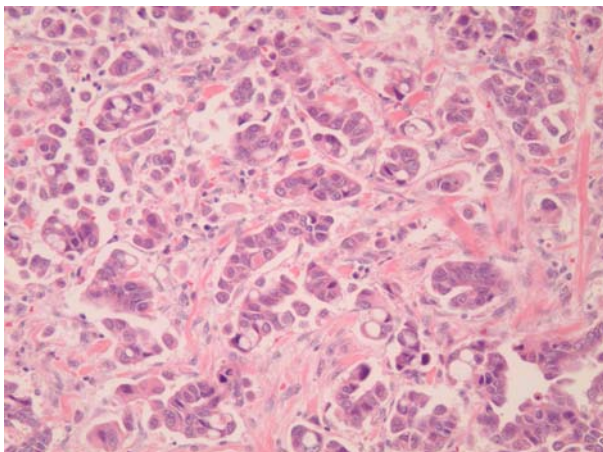


Fig. 3

REFERENCES

- 1) Yachida S, Nakanishi Y, Shimoda T, Nimura S, Igaki H, Tachimori Y, Kato H. Adenosquamous Carcinoma of the Esophagus: Clinicopathologic Study of 18 Cases. *Oncology*, 2004: pp. 218-225.
- 2) Takubo K. *Pathology of the Esophagus: An Atlas and Textbook*, 2nd ed. Springer, 2008.
- 3) Hamilton S, Aaltonen L. *World Health Organization: Pathology and Genetics of Tumours of the Digestive System*. IARC Press, Lyon, 2000.
- 4) Fenoglio-Preiser CM, et al. *Gastrointestinal Pathology: An Atlas and Text*, 3rd ed. Lipincott Williams & Wilkins, Philadelphia, 2008: pp. 124-125.