

Gastrointestinal and Liver Pathology at Rush

1750 W. Harrison St., Suite 570, Chicago, IL 60612 ♦ (312) 942-5227 phone ♦ (312) 942-4228 fax

Case of the Month Question – May 2009

Contributed by Drs. Maria McIntire and Shriram Jakate

70 year old man underwent an EGD for dysphagia and was found to have a nodule in the fundus of the stomach. Endoscopic ultrasound (Fig. 1), endoscopic imaging (Fig. 2), and H&E biopsies (Fig. 3 and 4) are provided below:

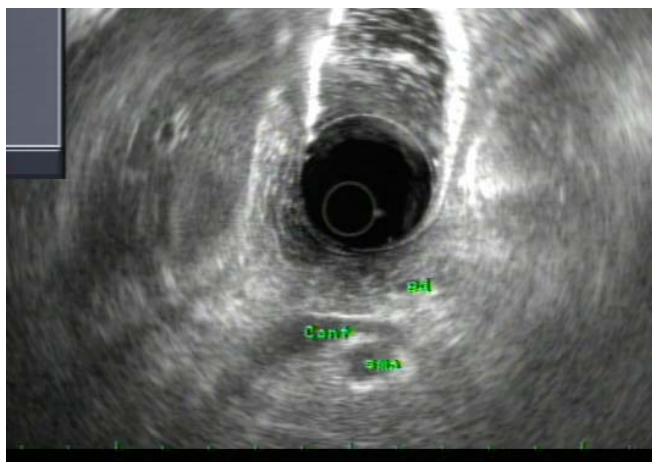

Fig. 1

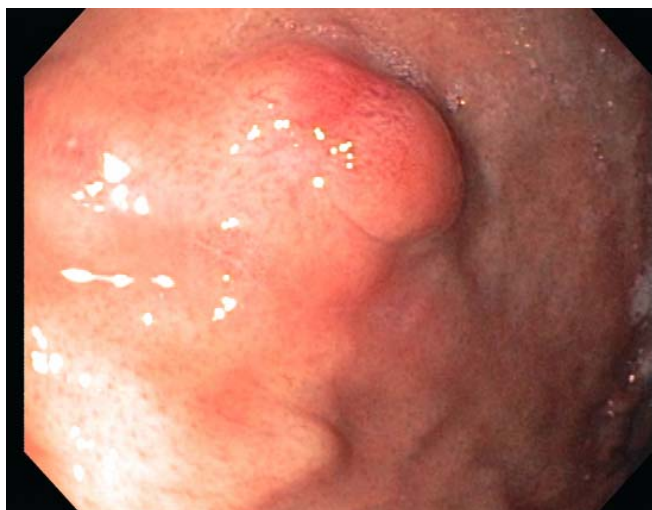

Fig. 2

Gastrointestinal and Liver Pathology at Rush

1750 W. Harrison St., Suite 570, Chicago, IL 60612 ♦ (312) 942-5227 phone ♦ (312) 942-4228 fax

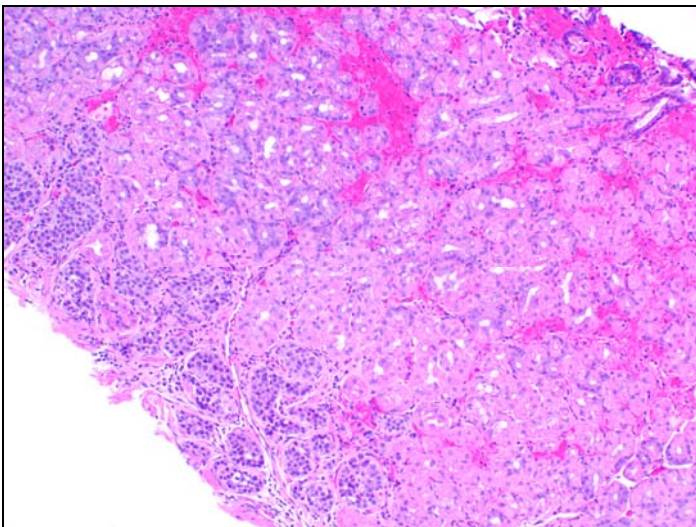
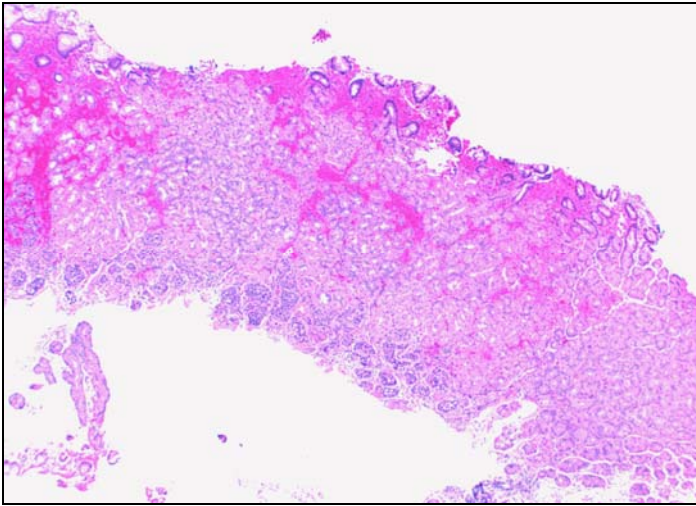


Fig. 3 and 4