

Gastrointestinal and Liver Pathology at Rush

1750 W. Harrison St., Suite 570, Chicago, IL 60612 ♦ (312) 942-5227 phone ♦ (312) 942-4228 fax

Case of the Month Answer – March 2009

Contributed by Drs. Dawn Bradly and Shriram Jakate

Diagnosis: Amyloidosis

Amyloidosis is a disorder of protein metabolism in which autologous proteins are deposited extracellularly in a characteristic abnormal fibrillar form ¹. There are six main types of amyloidosis: 1) primary or AL, 2) secondary or AA, 3) dialysis-related, 4) heritable, 5) age-related (senile) systemic, and 6) organ-specific. In the two most common forms of systemic amyloidosis, primary (AL) and secondary (AA amyloidosis), the major sites of clinically important amyloid deposition are in the kidneys, heart, and liver ¹.

Primary (AL) amyloidosis is the most frequent encountered type in developed countries and consists of deposition of protein derived from immunoglobulin light chain fragments ¹. It is often associated with plasma cell dyscrasias, multiple myeloma, B-cell malignancies, and Waldenstrom's disease ². Secondary (AA) amyloidosis is the most frequent encountered type in developing countries and consists of deposition of fibrils that are composed of fragments of the acute phase reactant serum amyloid A ¹. It is often associated with longstanding chronic inflammatory processes such as rheumatoid arthritis ². Hepatic involvement is common in both types and carries a poor prognosis, especially in the secondary (AA) type ^{2,3}.

Macroscopically, the liver may be markedly enlarged, pale, firm, of rubbery consistency, and may show a waxy, lardaceous appearance (Fig. A). Microscopically, extensive deposits of characteristic homogenous eosinophilic material are seen in blood vessels and in the sinusoids (Fig. B) ⁴. In the early stage of the disease, the histologic findings may be very subtle ⁴. As amyloid accumulates, the hepatocyte cell plates become atrophic and are eventually replaced ⁴. Congo Red stain (Fig. C) with polarization shows an apple-green birefringence.



Fig. A

Gastrointestinal and Liver Pathology at Rush

1750 W. Harrison St., Suite 570, Chicago, IL 60612 ♦ (312) 942-5227 phone ♦ (312) 942-4228 fax

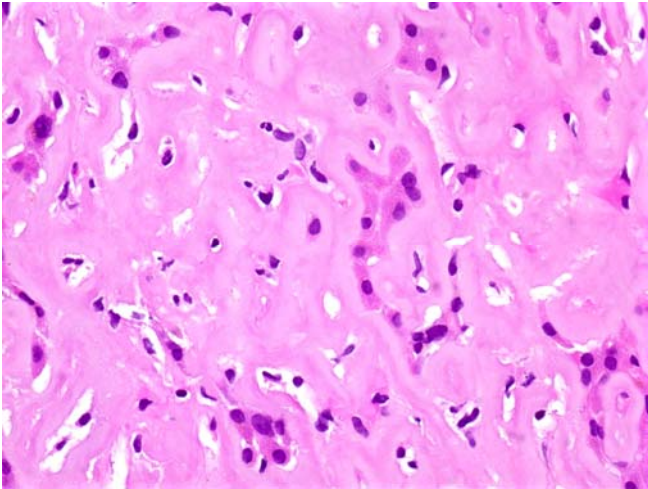


Fig. B

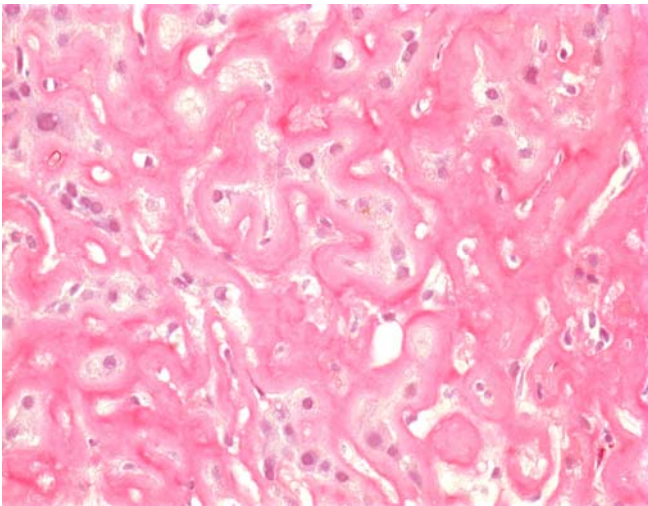


Fig. C

REFERENCES

- 1) Gorevic, PD. "An overview of amyloidosis." Up-to-Date, October 2008.
- 2) Lovat, et al. "The liver in systemic amyloidosis: insights from ^{123}I serum amyloid P component scintigraphy in 484 patients." *Gut*, 1998; 42: 727-734
- 3) MacSween, RNM et al. Pathology of the Liver, 3rd ed. Churchill Livingstone, Hong Kong, 1994, pp. 743-745.
- 4) Sternberg, SS et al. Diagnostic Surgical Pathology, 3rd ed. Lippincott Williams & Wilkins, Philadelphia, 1999, pp. 1543-1544.