

Gastrointestinal and Liver Pathology at Rush

1750 W. Harrison St., Suite 570, Chicago, IL 60612 ♦ (312) 942-5227 phone ♦ (312) 942-4228 fax

Case of the Month Question- April 2009

Contributed by Drs. Deborah Giusto and Shriram Jakate

Patient is a 6 year old boy who presents with gastrointestinal bleeding and multiple, cutaneous protuberant dark blue papules on the skin. Low power (Fig. 1) and high power (Fig. 2) views of his small bowel biopsy are provided below:

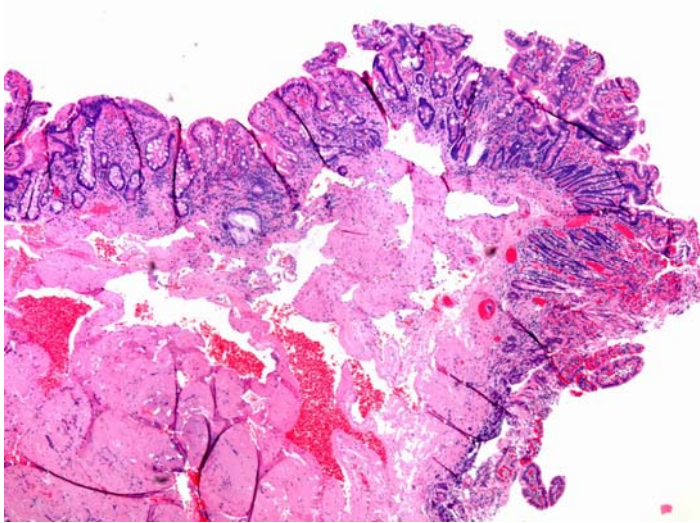


Fig. 1

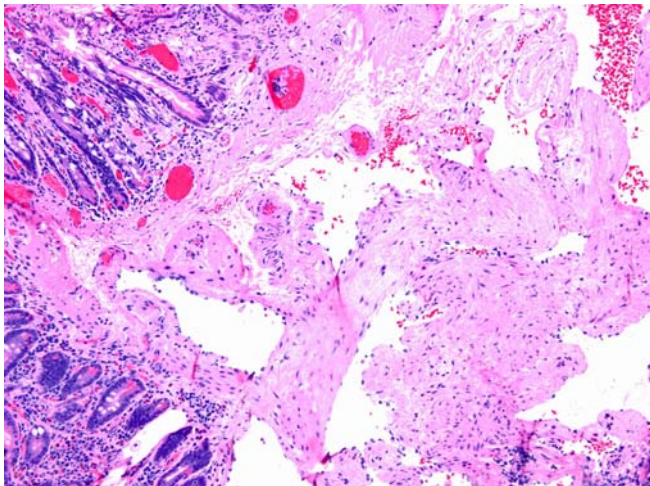


Fig. 2