

# Gastrointestinal and Liver Pathology at Rush

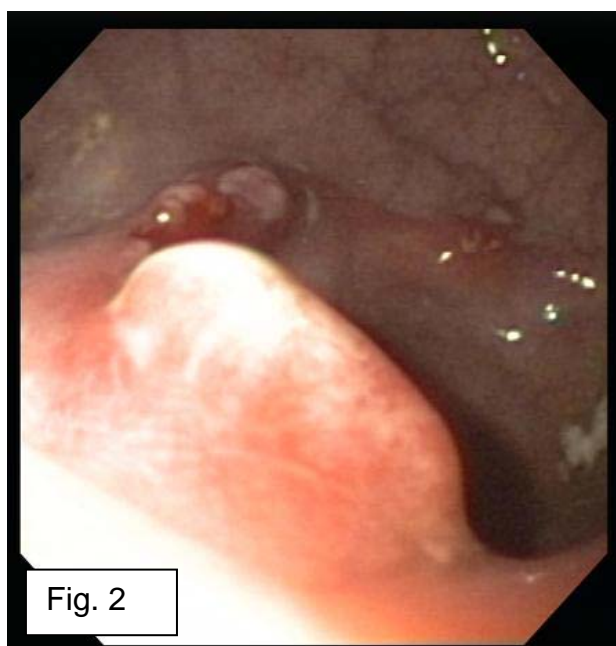
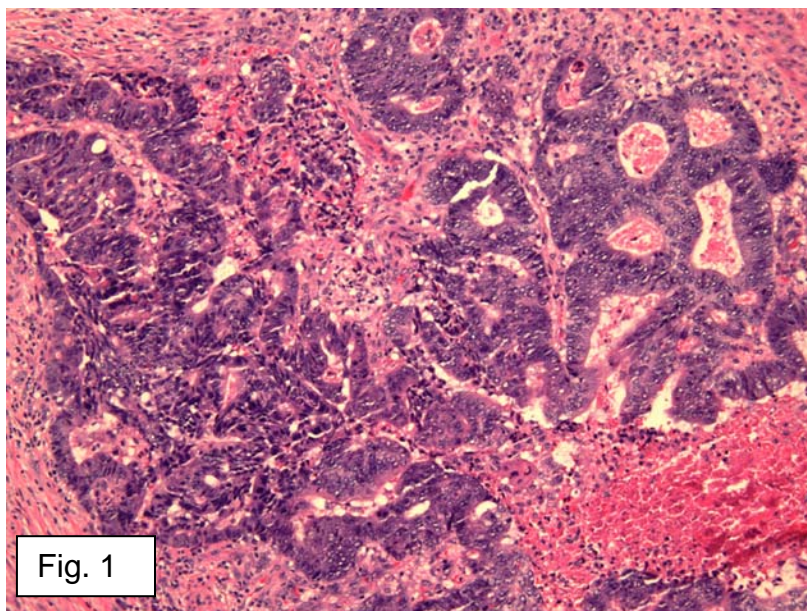
1750 W. Harrison St., Suite 570, Chicago, IL 60612 ♦ (312) 942-5227 phone ♦ (312) 942-4228 fax

---

## Case of the Month Question – May 2011

*Contributed by Drs. Jennifer Dettloff and Shriram Jakate*

A 72 y/o male has a history of colon cancer resected in 2001 (histology Fig. 1). Margins of resection were free of tumor. Screening colonoscopy 10 yrs later shows a polypoid mass near the previous anastomosis site (Fig. 2). The mass was biopsied (Fig. 3)



# Gastrointestinal and Liver Pathology at Rush

1750 W. Harrison St., Suite 570, Chicago, IL 60612 ♦ (312) 942-5227 phone ♦ (312) 942-4228 fax

---

