

# Gastrointestinal and Liver Pathology at Rush

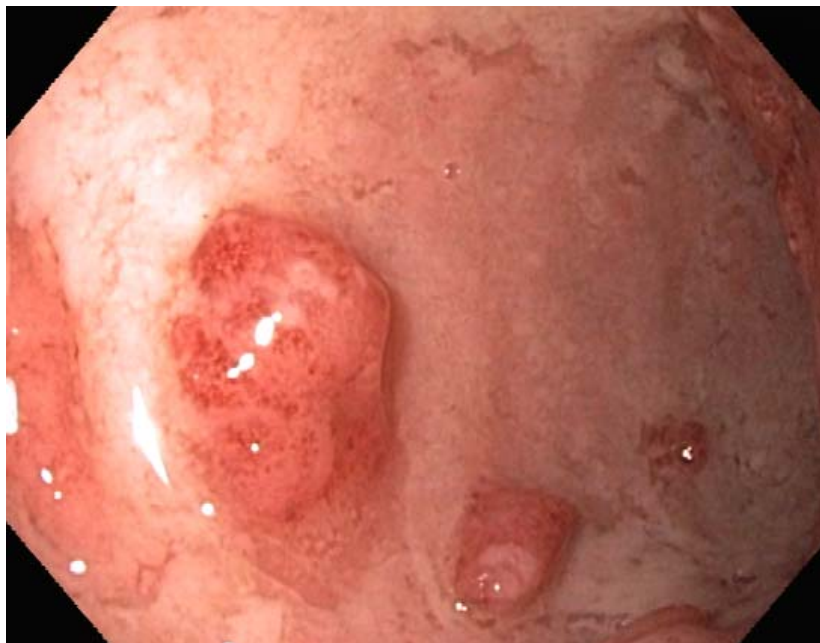
1750 W. Harrison St., Suite 570, Chicago, IL 60612 ♦ (312) 942-5227 phone ♦ (312) 942-4228 fax

---

## Case of the Month Question – March 2011

*Contributed by Drs. Ihab Lamzabi and Shriram Jakate*

A 51 y/o Caucasian female with a long history of metastatic breast carcinoma who was actively receiving chemotherapy until 3/2010 when she was diagnosed with ulcerative colitis after an episode of abdominal pain and bloody diarrhea. The patient was hospitalized several times since then for severe diarrhea. A follow-up colonoscopy (Fig. 1) was then performed to assess the evolution and the extent of the colitis and to rule out another cause of diarrhea especially CMV infection which can mimic IBD colitis.



**Fig. 1**