

# Gastrointestinal and Liver Pathology at Rush

1750 W. Harrison St., Suite 570, Chicago, IL 60612 ♦ (312) 942-5227 phone ♦ (312) 942-4228 fax

---

## Case of the Month Question – January 2011

*Contributed by Drs. Luis Blanco Jr. and Shriram Jakate*

A 55 y/o male with GERD on Nexium presents for screening colonoscopy. Past medical, surgical, and family histories are unremarkable. Physical examination is likewise unremarkable.

On colonoscopy, there were two polyps in the rectosigmoid at 25 cm (Fig.1). The polyps measured 1.5 cm and 6 mm respectively and were broad-based. The polyps were injected with a total of 5 mL of saline to raise the base and were then removed with hot snare polypectomy. Otherwise, the colon appeared to be normal.

On H & E, the polyps show scattered nodules of monomorphic lymphoid cells (Figs. 2 & 3).

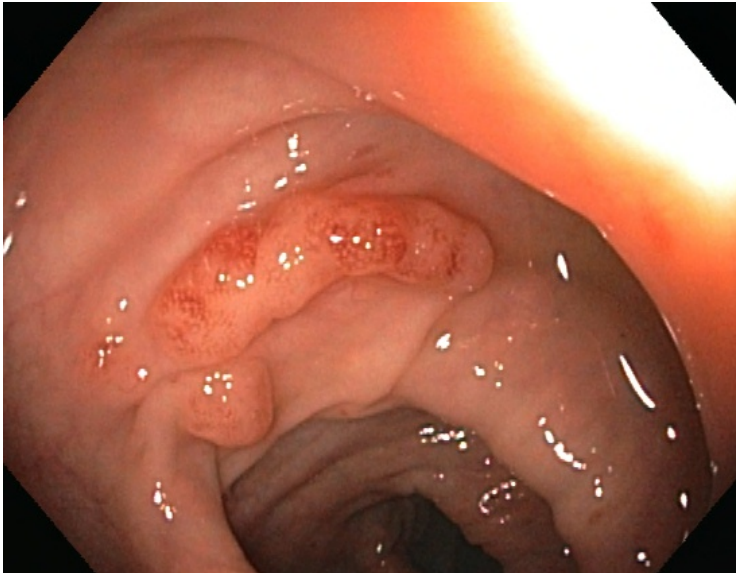


Fig. 1 Colonoscopy

# Gastrointestinal and Liver Pathology at Rush

1750 W. Harrison St., Suite 570, Chicago, IL 60612 ♦ (312) 942-5227 phone ♦ (312) 942-4228 fax

---

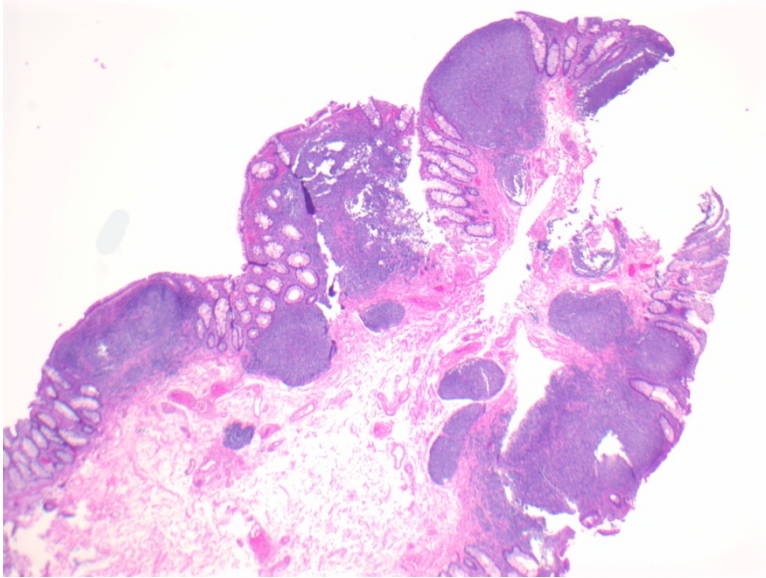


Fig. 2 Low magnification

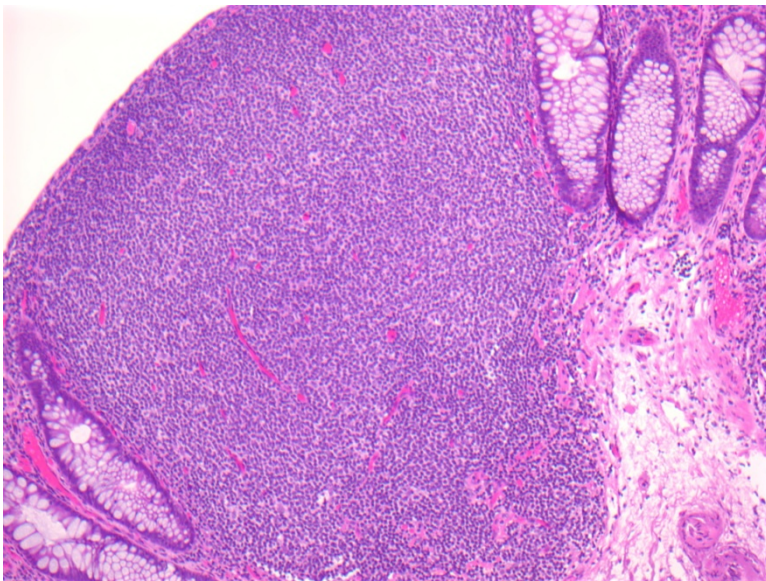


Fig. 3 High magnification